

The background features a dark blue gradient with a subtle pattern of white dots. Overlaid on this are several circular and semi-circular graphic elements in a lighter blue color. These include concentric circles, dashed lines, and solid lines, some with arrows indicating direction. A prominent feature is a large circular scale on the left side, with numerical markings from 140 to 260 in increments of 10. The text is centered in a clean, white, sans-serif font.

MUSCULOSKELETAL RADIOLOGY FELLOWSHIP

NORTHWESTERN UNIVERSITY
FEINBERG SCHOOL OF MEDICINE
NORTHWESTERN MEMORIAL HOSPITAL
CHICAGO , ILLINOIS

FELLOWSHIP GOALS

- Prepare graduating fellows to be able to provide high-level subspecialty Musculoskeletal (MSK) Radiology services in a variety of practice settings
 - Fellows always have attending oversight
 - Graduated responsibilities so that fellows feel comfortable running an MSK Radiology practice
- Well-balanced fellowship training in all aspects of MSK Radiology clinical practice
 - Magnetic resonance imaging (MRI)
 - Computed tomography (CT)
 - Ultrasound
 - Conventional radiography (CR)
 - Procedures

HISTORY

- Pre-2012- Abdominal and MSK-Predominant MRI fellowship served as part-time MSK fellows
 - 2009-2010 class produced two MSK radiologists
- 2012- first official MSK Radiology fellowship position created from MRI fellowship
- 2014- moved base of MSK Radiology operations into the Lavin Pavilion
 - Establish closer ties with Orthopaedic Surgery and Rheumatology
- 2019- approved for second fellowship position
- 2020- first 2-person fellowship class



David Levi, MD
Atlantic Medical Imaging, NJ

2009-2010:
Our first “unofficial”
fellows



Shawn Haji-Momenian, MD
George Washington University, Wash. DC

LAVIN PAVILION

- Established in October 2014
- Directly connected to Northwestern Memorial Hospital (NMH)
- Serves as main outpatient facility for NMH
 - 17th floor dedicated to multimodality imaging and preoperative diagnostic testing
 - Main MSK Radiology Reading room
 - Contains the Center for Comprehensive Orthopaedic and Spine Care (CCOSC), which is an Orthopaedic center of excellence
 - 5 floors of ambulatory operating rooms and clinical space
 - Integrated MSK Radiology consult room and fluoroscopy rooms in the 13th floor clinic
 - Conference room from which joint Orthopaedic and Radiology conferences are held
 - 2021- expansion of spine center to the 14th floor, which contains dedicated space for MSK radiology
- Currently, entire fellowship occurs on NMH campus



Northwestern Memorial Hospital Lavin Pavilion

EVANSTON SPORTS MEDICINE

- “Northwestern Medicine Sports Medicine and Imaging Center Evanston”
 - Outpatient Sports Medicine center integrating diagnostic MSK imaging into the sports medicine clinical practice
 - Opened December 2022
- Full suite of imaging modalities
 - Fluoroscopic and US-guided MSK procedures
- Adjacent to the Northwestern University undergraduate campus
 - Strong relationship with NU Athletics
- MSK Radiology staffs center 2 days/week
 - Potential for MSK Radiology fellows to work with attending staff at this site

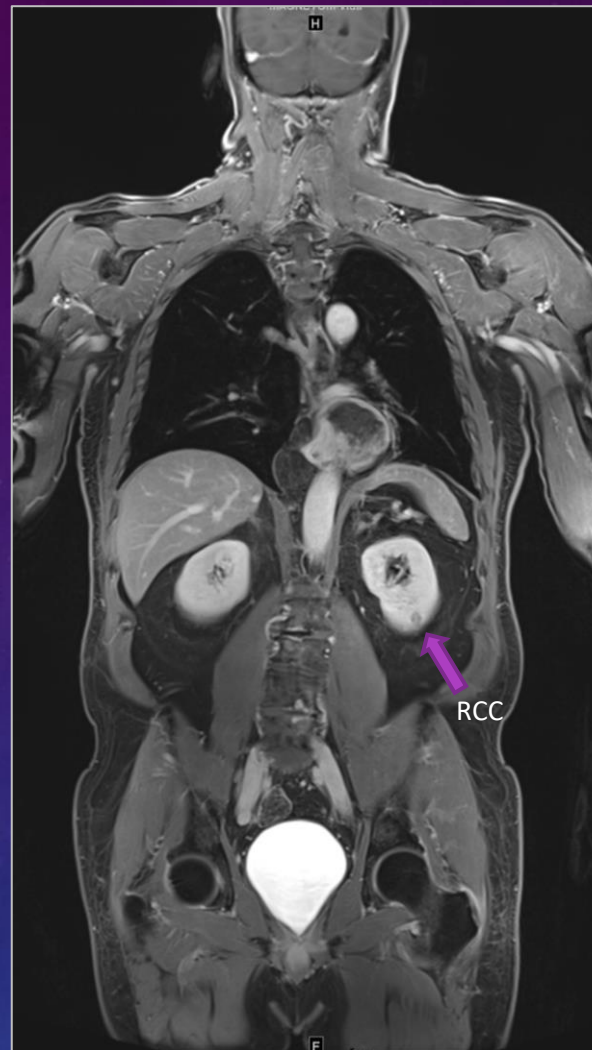


FELLOW SCHEDULE

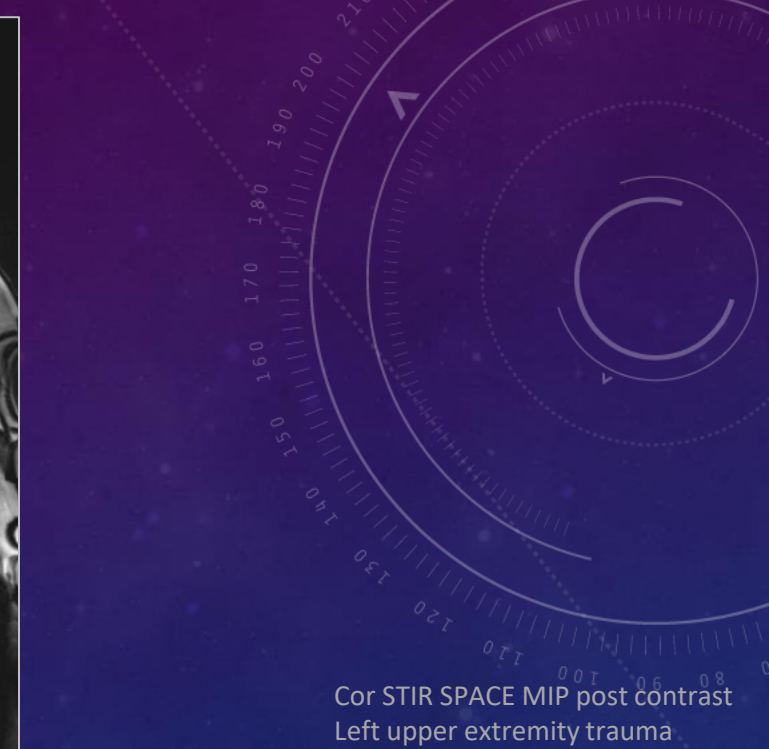- Two Fellow Schedule-
 - One fellow is on diagnostic service and primarily responsible for facilitating main reading room activities
 - Primarily reading MRI and responsible for overseeing MRI protocols
 - Serves as initial point person in the reading room for other trainees and technical staff
 - ½ day of plain film/CT
 - ½ day of ultrasound
 - Other fellow is on procedural service and has a mix of CT, ultrasound and fluoroscopy-guided procedures
 - Responsible for interfacing with clinical and radiology services and facilitating scheduling of procedures
 - Spine fluoroscopic procedures in second half of the year
- One Fellow Schedule-
 - Revert to single fellow schedule when one fellow is off service
 - On MRI all day Monday and Friday, and Wednesday and Thursday AM
 - Procedures Tuesday AM and Wednesday PM
 - Ultrasound Tuesday PM
 - Plain films/fluoro Thursday PM

MRI

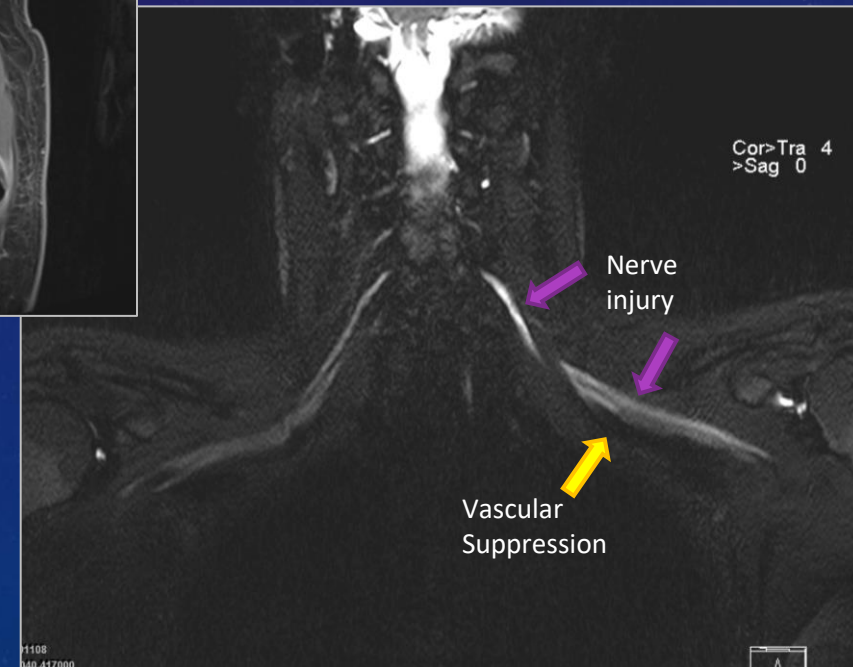
- Currently all MRIs performed on Siemens scanners
- Nine 1.5-T, nine 3-T clinical magnets and one PET-MR 3-T scanner
- Perform 60-90 MSK MRIs/day
 - Highest volumes on Mondays and Fridays
 - Approximately 60-70 MSK MRIs scanned on other days
- Wide variety of MSK MRI indications, including sports-imaging, arthritis, cartilage specific imaging, primary and metastatic tumors, metal implants, MR neurography and whole-body oncologic MRI
 - Diagnostic spine imaging is done by neuroradiology



WB MRI T1W FS post contrast
Li Fraumeni patient



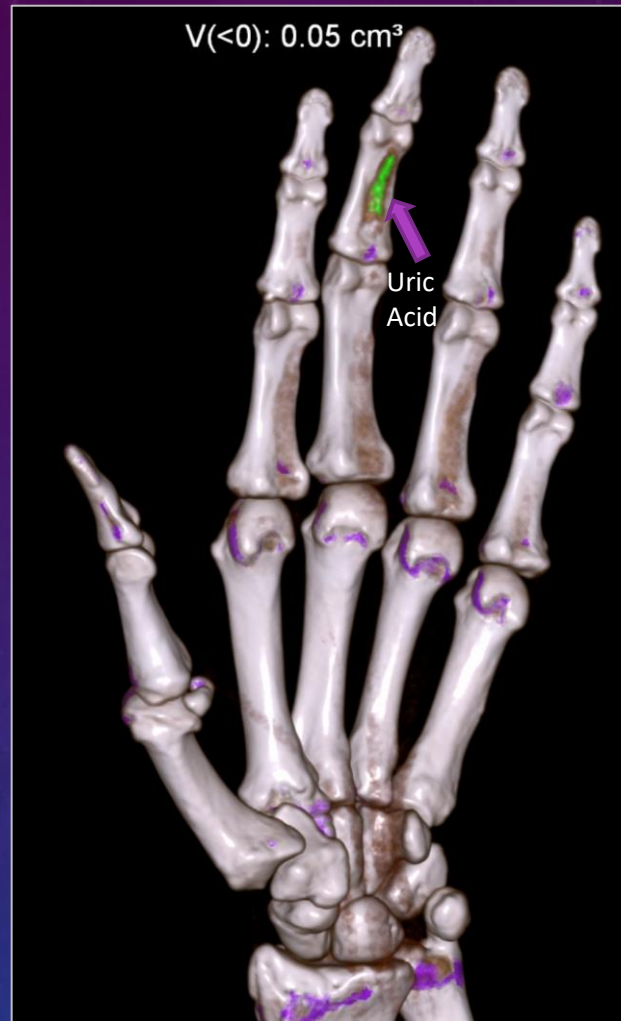Cor STIR SPACE MIP post contrast
Left upper extremity trauma



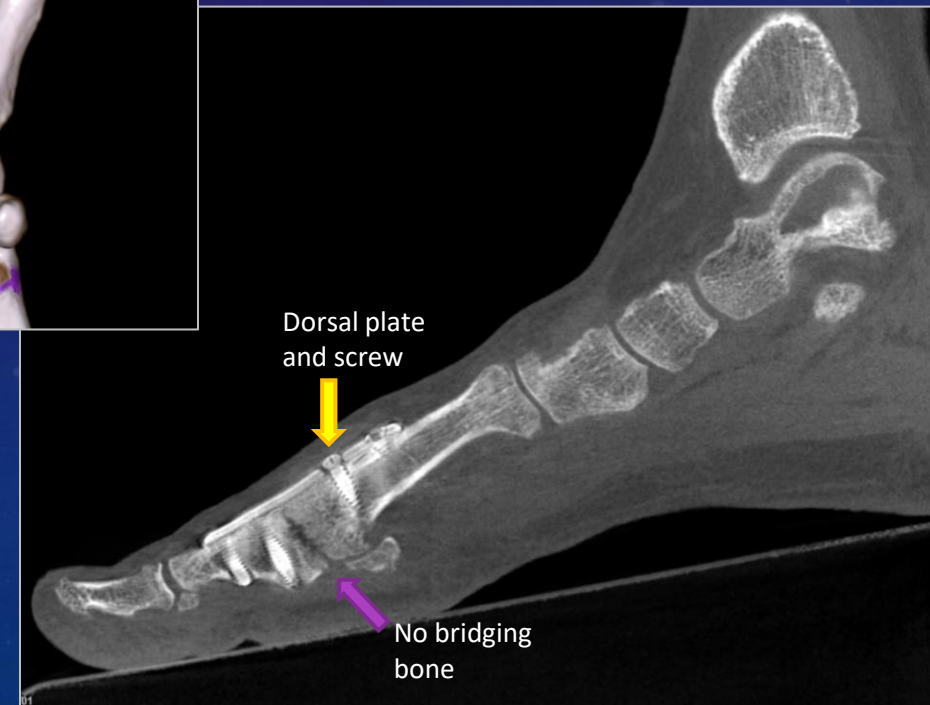
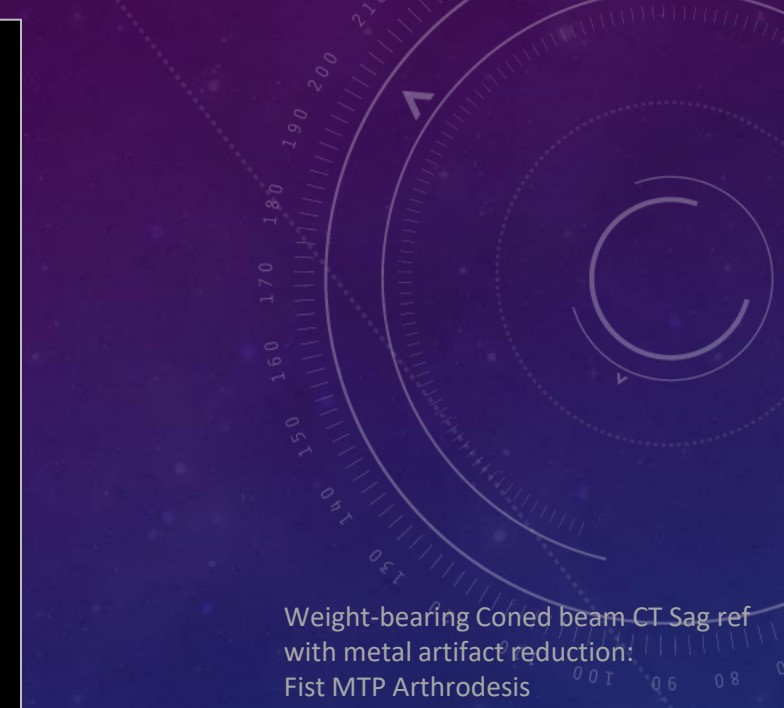M108
040.417000

CT

- 10 Siemens CT scanners in the system
 - 1 Siemens Photon Counting CT
 - 4 dual-source, dual energy and 1 single source dual energy
 - Gout, bone marrow and iodine mapping assessment
- 2 coned-beam extremity CTs in the Orthopaedic Clinic and Old Irving Park
 - Allows low radiation dose, weight-bearing studies
 - Metal artifact reduction and 3D reformatting capabilities
 - Hand/wrist and foot/ankle are most common
- Do 10-25 extremity MSK CTs/day

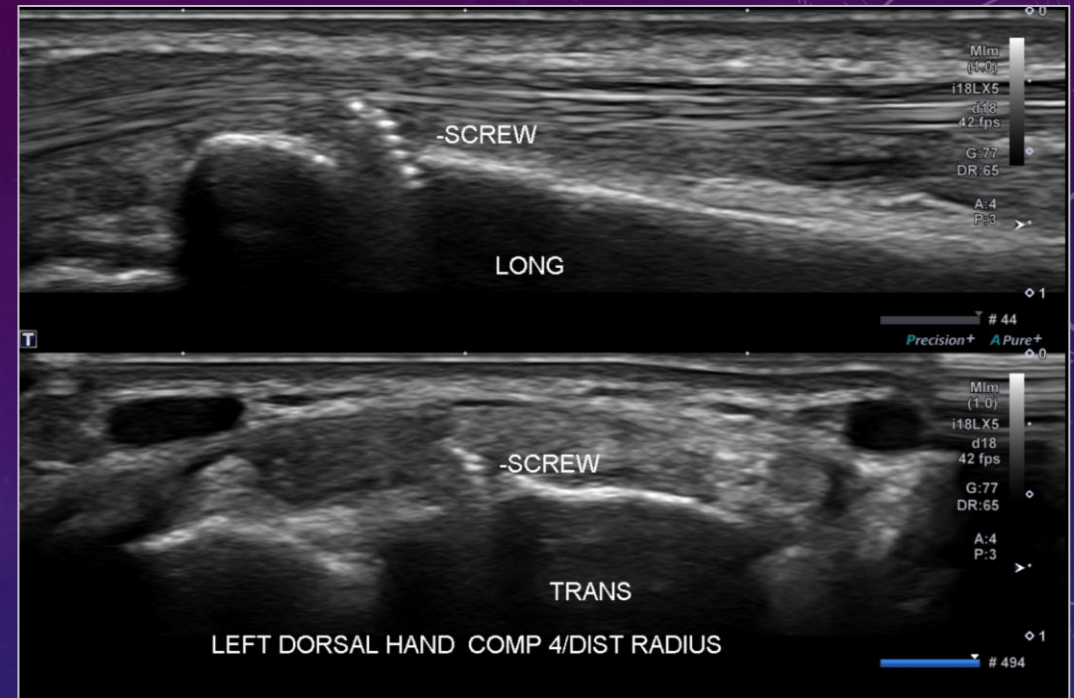


DECT 3D ref. surface rendering:
Gout

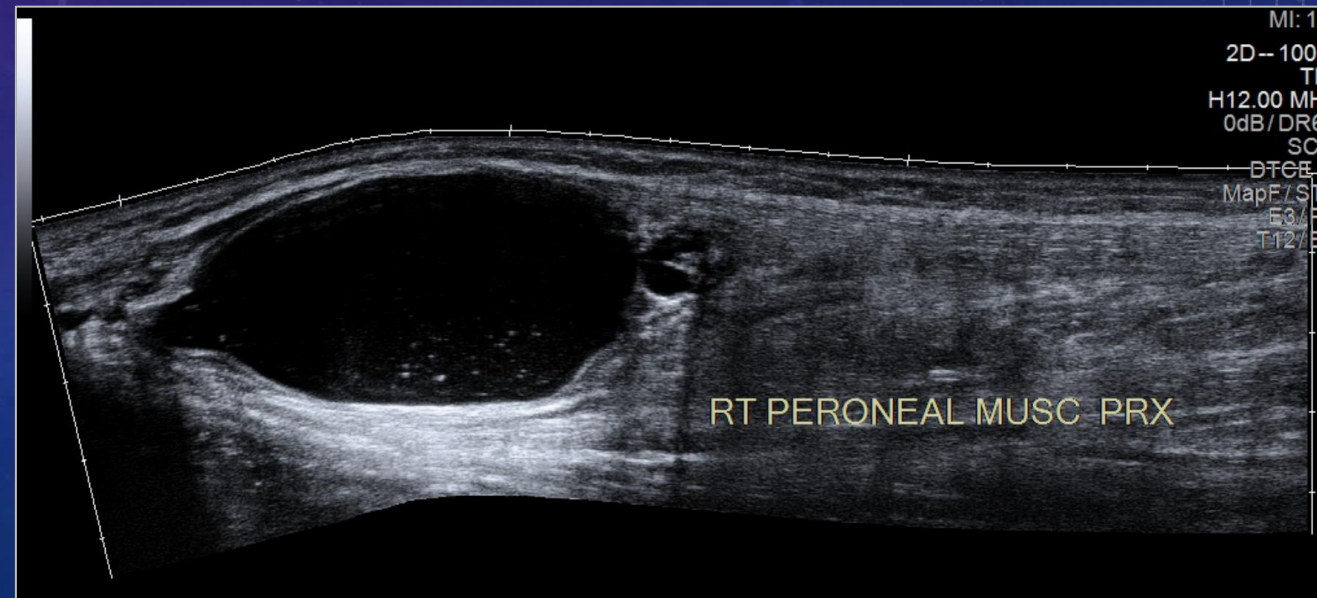


ULTRASOUND

- Elective MSK ultrasound done 3 days/week
 - Mix of diagnostic and procedural
 - Approximately 15-20 scheduled cases/day
 - Daily add-on elective and urgent inpatient/ED cases (5 day/week)
- Two MSK US rooms near the 17th floor reading room in the Lavin building
- 5 experienced MSK sonographers, with 1-2 others in training
- Diagnostic exams include soft tissue masses, tendon and ligament assessment, inflammatory arthritis, hardware complications, dynamic assessment for impingement, peripheral nerve assessment.
- Goal for MSK fellow to initially shadow the sonographers and ultimately be able to perform his or her own studies under attending guidance
 - Fellow should do at least ½ day of ultrasound/week



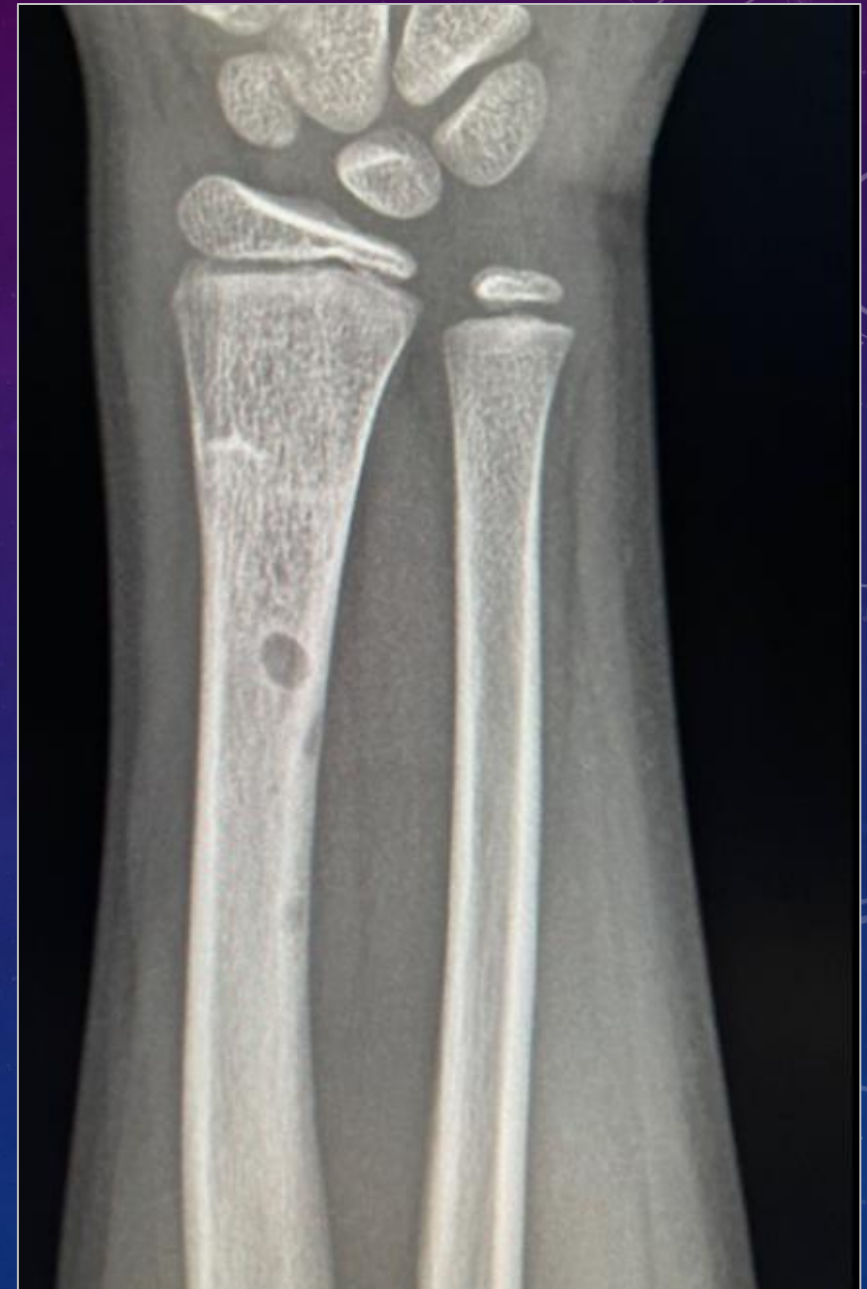Fixation screw impinging 4th EDC tendon



Panoramic view of complex ganglion from proximal tibiofibular joint impinging on CPN

CONVENTIONAL RADIOGRAPHY

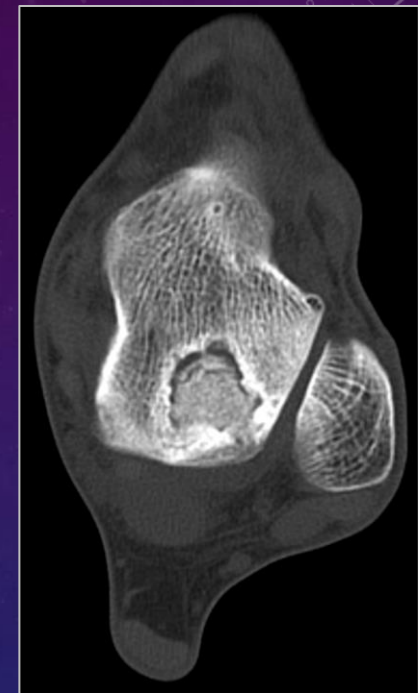
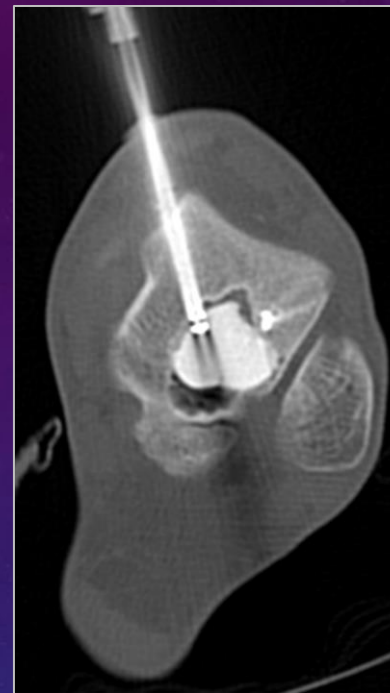- Approximately 150-200 MSK plain films done/day
- Spine and head and neck studies read by neuro
- Mainly interpreted by first year residents
- MSK fellow should expect to do plain film $\frac{1}{2}$ day/week to maintain skills from residency, improve accuracy and speed



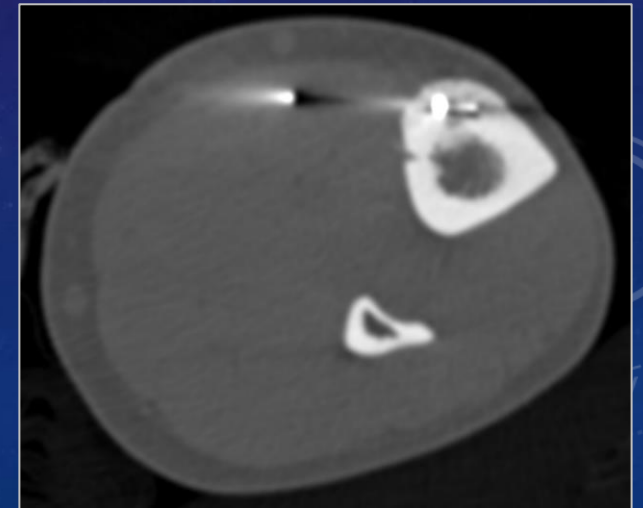
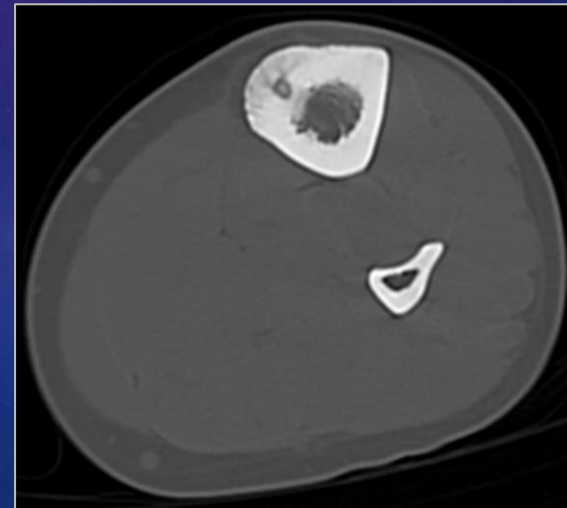
AP forearm radiograph:
Distal radial transverse buckle fracture with posttraumatic fat globule

PROCEDURES

- Occur in 4 settings
 - Interventional Radiology (4th floor of main hospital)
 - Bone biopsies and soft tissue biopsies and some aspirations
 - Bone marrow aspirations
 - Thermal and chemical ablations
 - Occasional cement and biological scaffold stabilizations
 - Ultrasound (mostly on Lavin 17th floor)
 - Diagnostic and therapeutic palliative injections
 - Dry needling and Lavage
 - Tissue sampling
 - Fluoroscopy (Lavin 13th floor)
 - Arthrography
 - Palliative joint and trigger point injections
 - Fluoroscopy (Lavin 14th floor)- Spine



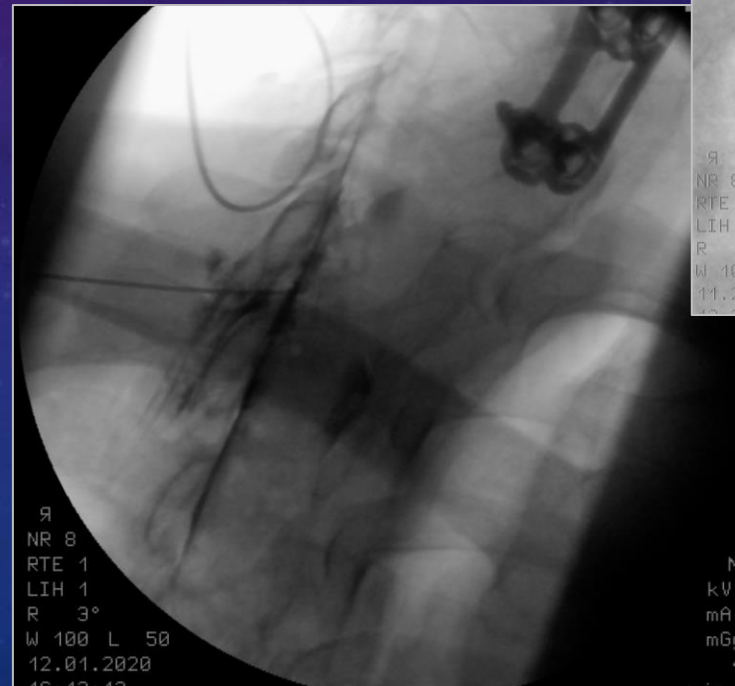
Intraprocedural and postprocedural axial CT images of talus:
Injection of bone graft substitute



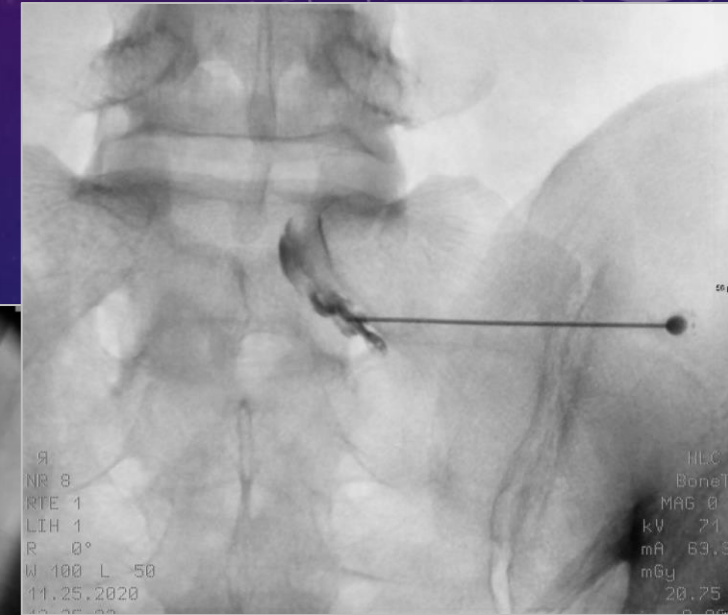
Preprocedural and intraprocedural axial CT images of mid-tibia:
Radiofrequency Ablation of osteoid osteoma

FLUOROSCOPICALLY-GUIDED SPINE INJECTIONS

- Began fluoroscopically-guided spine injection service in 2015 as a service to neurosurgical and orthopaedic spine surgeons in CCOSC
- 5-12 procedures/ ½ day
- Perform:
 - Cervical spine interlaminar epidural and facet steroid injections
 - Lumbar spine transforaminal and interlaminar epidural and facet injections
 - Sacral hiatus caudal injections
 - Sacroiliac joint injections
 - Ganglion impar injections



Contralateral oblique spot fluoroscopic image:
T1-T2 interlaminar epidural steroid injection



AP spot fluoroscopic image:
S1 transforaminal nerve root steroid injection

SPORTS IMAGING

- NMH provides medical and Orthopaedic services to the Chicago Cubs
 - See a full spectrum of upper extremity overhead throwing injuries
- Northwestern University Athletics
 - Imaging through Evanston facility
 - Football, basketball and Olympic sports
- Long-standing relationship with NBA to provide pre-draft medical and Orthopaedic assessment of prospective draft candidates
 - See patterns of lower extremity injuries in elite level basketball players
- Occasional Blackhawks



ACADEMIC INSTRUCTION

- Initial lecture series
 - Introduction to MSK MRI techniques and protocolling, routine joint MRI with focus on knee and shoulder
- Periodic didactic lectures
 - Intermittent throughout the year
- Sectional conferences
- Multidisciplinary conferences
- Research component
- Fellow grand rounds
- Optional experiences

CONFERENCES

- Sectional conferences
 - QA/QM- every other month
 - Journal Club
 - Interesting Cases
- Multidisciplinary
 - Weekly sarcoma conference- 1 hour every Tuesday
 - 1 week is Orthopaedic sarcoma
 - 1 week is soft tissue sarcomas
 - Radiology/Arthroscopy correlation conference
 - Every 6 weeks at 6:15 AM
 - Rheumatology
 - Every 8 weeks
- Chicagoland MSK Radiology Interest Group
 - Saturday mornings 3 times/year in NMH Radiology department
 - All academic programs in the city and several high volume private practices share cases and experiences
 - Chance for networking and job seeking

RESEARCH REQUIREMENT

- Fellow should identify and develop a project that can be completed within the year
 - Should be done with a faculty mentor
- Goal is to submit a manuscript to a PubMed-cited journal
- Can be primary literature, case series, technical note or review article
- Should help fellows-
 - Understand how to identify and interpret relevant literature
 - Design an appropriate study and patient cohort
 - Navigate internal review board for study approval when appropriate
 - Apply for some academic or hybrid academic positions

Review paper

Magnetic resonance imaging of the wrist and hand

Ravi Vassa^{EF}, Ankur Garg^{EF}, Imran Muhammad Omar^{EF}

Department of Radiology, Northwestern University Feinberg School of Medicine, USA

Imaging of Total Ankle Arthroplasty: Normal Imaging Findings and Hardware Complications

Imran M. Omar, MD¹ Samir F. Abboud, MD¹ Jonathan M. Youngner, MD¹

¹ Department of Radiology, Northwestern University Feinberg School of Medicine, Chicago, Illinois

Address for correspondence Imran M. Omar, MD, Department of Radiology, Northwestern University Feinberg School of Medicine, 676 North Saint Clair Street, Suite 800, Chicago, IL 60025 (e-mail: iomar@nm.org).

Semin Musculoskelet Radiol 2019;23:177-194.

Skeletal Radiology (2019) 48:605-613
<https://doi.org/10.1007/s00256-018-3087-1>

TECHNICAL REPORT



Initial experience with dual-energy computed tomography-guided bone biopsies of bone lesions that are occult on monoenergetic CT

Michael C. Burke¹ • Ankur Garg¹ • Jonathan M. Youngner¹ • Swati D. Deshmukh¹ • Imran M. Omar¹

Received: 18 July 2018 / Revised: 24 September 2018 / Accepted: 1 October 2018 / Published online: 20 October 2018
© ISS 2018

medical communications | sciendo

Cite as: Lee SK, Serhal AM, Serhal M, Michalek J, Omar IM: The role of high-resolution ultrasound and MRI in the evaluation of peripheral nerves in the lower extremity. J Ultrason 2023; 23: e328-e346. doi: 10.15557/JoU.2023.0038.

Submitted:
07.08.2023
Accepted:
22.08.2023
Published:
30.10.2023

The role of high-resolution ultrasound and MRI in the evaluation of peripheral nerves in the lower extremity

Steven Kyungho Lee^{ORCID}, Ali Mostafa Serhal^{ORCID}, Muhamad Serhal^{ORCID}, Julia Michalek^{ORCID}, Imran Muhammad Omar^{ORCID}

FELLOW GRAND ROUNDS

- Given in the last quarter of the academic year
- Roughly 45 minutes with 10-15 minutes for Q and A
- Meant to examine newer concepts in MSK radiology or relevant orthopaedic or rheumatologic practice
- Fellow can finish fellowship with an established advanced lecture in MSK radiology that they can either give when interviewing for academic positions, give to trainees outside of NMH or to referrers in order to establish themselves as having expertise in the field

CALL

- MSK-style call
 - Changed in 2023-2024 academic year
 - Fellow on call once every 4 week block
 - Weekend in person readouts
 - Focus on inpatient and ED cross-sectional studies and possibly stat outpatient studies
 - MSK plain films
 - ? Weekday pager call from 5-8 pm

OTHER TRAINEES ON MSK RADIOLOGY

- Fellows
 - Body and MSK-predominant MRI fellows
 - Do about 20% their service on MSK rotation
 - Limited to MRI and possible CT/plain film depending on service needs
 - Fellows from other services on elective
- Residents
 - First year residents are expected to do plain film and some MSK CT toward the end of the rotation
 - Upper year residents are expected to do MSK MRI, and other diagnostic imaging modalities depending on service needs
 - Mini-fellows- expected to participate in the sectional clinical and academic activities similar to MSK fellows
- MSK fellow is a primary resource to other trainees and should work with them on protocols, consultations and emergent patient events
 - The MSK fellows should share these responsibilities and are not expected to be the only ones participating

ELECTIVE TIME

- 4 weeks of elective time
- Split into first and second halves of year
 - Staggered between fellows
- No limitations provided there is significant educational benefit
- Examples:
 - Neuroradiology to perform diagnostic spine imaging
 - Pediatric Radiology under guidance of Jonathan Samet to improve understanding of pediatric MSK Radiology
 - Nuclear Medicine
 - Women's imaging
 - Off-site electives are possible



Lurie Children's Hospital

OPTIONAL ACTIVITIES

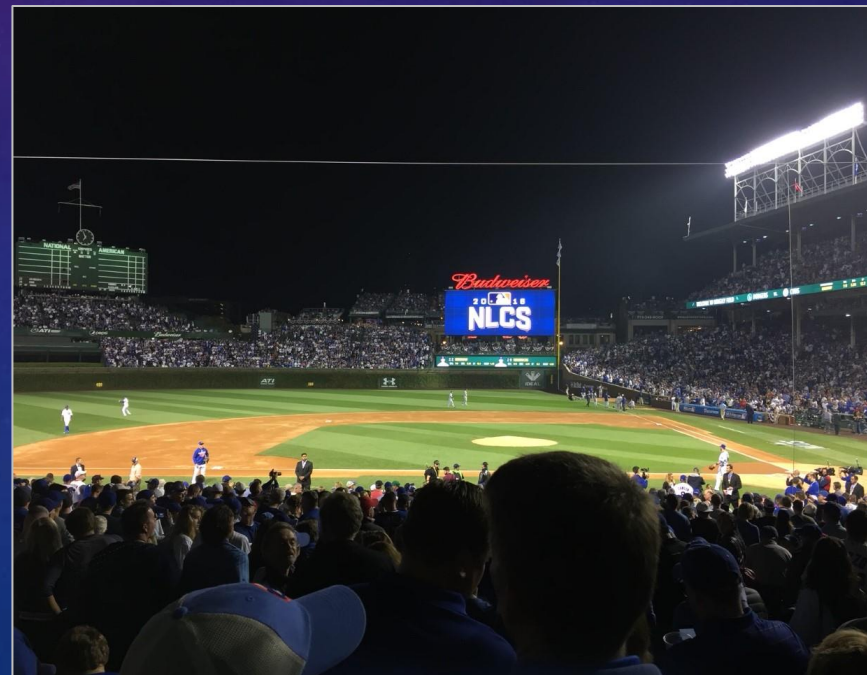- **First Year Medical Student Anatomy Lab**
 - Spend time in anatomy lab when the first year medical students are dissecting extremities
 - Opportunity to dissect structures usually only seen on imaging
 - Expose medical students to MSK radiology early in their training
- **Clinic Time**
 - Orthopaedic Surgery
 - Sports Medicine
 - Rheumatology

SOCIAL EVENTS

- Chances for team bonding and for attendings and fellows to see each other outside of work
- Many of us are sports fans
 - Opportunities to see games, such as Cubs, Blackhawks and Northwestern football
- Periodic dinners
- End of year graduation dinner



United Center from Dr. Terry's seats



Wrigley Field 2016 NLCS Game 1



2015 Stanley Cup

PAST FELLOWS


- 2011-2012 Saquib Khawar, MD
 - Staff Radiologist; Central Illinois Radiological Associates
- 2012-2013 Mauricio Galizia, MD
 - Cardiovascular Radiologist; University of Iowa, Iowa City, IA
- 2013-2014 Nick Morley, MD
 - Musculoskeletal Radiologist; Marshfield Clinic- Eau Claire Campus
- 2014-2015 Eric Tarkowski, MD
 - Musculoskeletal Radiologist; Northwestern Central DuPage Hospital, Winnefield, IL
- 2015-2016 Kulia Kakarala, MD
 - Staff Musculoskeletal Radiologist; Texas Tech University Medical Center Health System, Lubbock TX
- 2016-2017 Jonathan Youngner, MD
 - Staff Radiologist; Cleveland Clinic, Cleveland OH
- 2017-2018 Michael Burke, MD
 - AMITA Health Saint Francis Hospital; Evanston IL



Kulia Kakarala, MD



Jonathan Youngner, MD



Eric Tarkowski, MD



Michael Burke, MD

PAST FELLOWS

- 2018-2019 Samir Abboud, MD
 - Chief Emergency Radiology; Northwestern Memorial Hospital, Chicago, IL
- 2019-2020 Ravi Vassa, MD
 - Staff Musculoskeletal Radiology; Texas Radiology Associates, Dallas, TX
- 2020-2021 Bradley Herynk, MD
 - Musculoskeletal Radiologist; Northwestern University, Chicago, IL
- 2020-2021 Alexander Skopec, MD
 - Staff Radiologist; Colorado Imaging Associates, Denver, CO
- 2021-2022 Bradley Adams, MD
 - Staff Radiologist; Houston Radiology Associated; Houston, TX
- 2021-2022 Patrick Hackler, MD
 - Staff Radiologist; Midwest Radiology, Minneapolis, MN
- 2022-2023 Steven Lee, MD
 - Staff Radiologist, Radiology Associates of North Texas, Dallas, TX



Patrick Hackler, MD



Bradley Adams, MD



Ravi Vassa, MD



Samir Abboud, MD

PAST FELLOWS

- Through the 2022-2023 academic year there have been 14 total fellows
 - 9 from Northwestern
 - 5 from elsewhere
- 8 purely in private practice
- 2 in hybrid private/academic practices
- 4 in academic positions

CURRENT FACULTY

- Ronald Hendrix, MD
 - University of Chicago Fellowship 1974
- Renee Yap, MD
 - Massachusetts General Hospital MSK Radiology Fellowship 1997
- Imran Omar, MD
 - Thomas Jefferson University MSK Radiology Fellowship 2006
- Ankur Garg, MD, MBA
 - UCSF MSK Radiology Fellowship 2013
- Ajay Chapa, MD, MBA
 - Rush University Body Imaging and MSK Fellowship 2012
- Bradley Herynk, MD
 - Northwestern University MSK Radiology Fellowship 2021
- Ali Serhal, MD
 - Northwestern University MRI/MSK Radiology Fellowship 2021
- Jonathan Samet, MD
 - Johns Hopkins University MSK Radiology Fellowship 2013
 - 4 days/week at Lurie Children's Hospital and 1 day/week at NM
- David Sandman, MD (joining in July 2023)
 - UCLA MSK Radiology Fellowship 2010



Renee Yap, MD



Ankur Garg, MD



Bradley Herynk, MD



Ajay Chapa, MD

CONTACT

- Fellowship Program Director: **Imran M. Omar, MD**
 - Email- iomar@nm.org
- Fellowship Coordinator: **Kathryn Murphy**
 - Email- Kathryn.murphy@nm.org